



Pulmonary vein isolation using an occluding cryoballoon for circumferential ablation: feasibility, complications, and short-term outcome

Yves Van Belle*, Petter Janse, Maximo J. Rivero-Ayerza, Andrew S. Thornton, Emile R. Jessurun, Dominic Theuns, and Luc Jordaens

Clinical Electrophysiology Unit, Department of Cardiology, Thoraxcentre, Erasmus Medical Centre, Dr Molewaterplein 40, Room BD416, 3015 GD Rotterdam, The Netherlands

Received 12 March 2007; revised 1 May 2007; accepted 10 May 2007

KEYWORDS

Clinical electrophysiology;
Atrial fibrillation;
Pulmonary vein isolation;
Catheter ablation;
Cryothermal;
Balloon

Aims To assess safety, feasibility and short term outcome of pulmonary vein (PV) isolation in paroxysmal atrial fibrillation (AF) with a cryoballoon.

Methods We consecutively treated 57 patients with a double lumen 23 or 28 mm cryoballoon. The acute results, complications and follow-up over the first three months were analysed, using a comprehensive and intensive follow-up period.

Results During 57 procedures, 185 of 220 targeted PV's were successfully isolated using the cryoballoon (84%) (balloon group, 33 patients). In 33 veins (15%) an additional segmental isolation (hybrid group, 24 patients) was necessary with a standard cryocatheter to achieve isolation. The average procedure times were respectively 211 ± 108 and 261 ± 83 minutes (NS), the average fluoroscopy times 52 ± 36 and 66 ± 33 minutes (NS). The number of balloon applications did not differ between both groups: respectively a median 9 (4–18) and 10 (5–17) (NS). We observed four phrenic nerve paralysis after ablation of the right superior PV: two resolved immediately after cessation of the cryoenergy, one recovered after 3 months, one persisted up to 6 months. A daily transtelephonic rhythm recording showed a significant drop in mean AF burden from 24% to 10%, 8% and 5% during the three consecutive months of follow-up ($p < 0.01$ versus baseline). No differences were observed between the treatment groups. 34 patients (60%) were completely free from AF after a single procedure.

Conclusions Balloon cryoablation of the pulmonary veins with additional segmental isolation if necessary, is a good approach for patients presenting with paroxysmal AF, showing a significant reduction in AF burden after a single procedure. The major complication seems to be phrenic nerve paralysis after ablation of the right superior PV, but this is potentially reversible over several months.

Introduction

Pulmonary vein isolation (PVI), either segmental or circumferential, has become an important treatment of patients with atrial fibrillation (AF). Reports have been published that show up to 85% freedom of paroxysmal AF during long-term follow-up.^{1–9} A large number of different approaches and techniques exist. The procedure remains technically challenging with a significant number of complications such as thrombo-embolism,¹⁰ PV stenosis,^{11,12} atrio-esophageal fistulae,^{13–17} and left atrial (LA) flutter.¹⁸ Innovative new technologies are being developed to make isolation safer and easier.

Cryoablation has been promising because of low thrombogenicity and absence of PV stenosis, but the longer procedure and fluoroscopy times have limited this approach to segmental isolation.¹⁹ Recently, the development of

balloon technology has opened the way for several novel approaches to isolation with new energy types (ultrasound, focused ultrasound, laser and cryotherapy). Cryoballoon experiments have been shown to be feasible and safe in animals.^{20,21} Our aim was to publish our initial experience in humans, not only to describe the procedural success rate but also to assess short-term efficacy in treatment of paroxysmal AF. We have adopted an intensive follow-up method, using daily event monitoring.²²

Methods

Patients

Patients with documented paroxysmal AF at two or more occasions were accepted as candidates. Exclusion criteria were LA dimension >50 mm measured in the parasternal long axis, as assessed with transthoracic echocardiography, valvular heart disease, and advanced age.

* Corresponding author. Tel: +31 104633991; fax: +31 104634420.
E-mail address: y.vanbelle@erasmusmc.nl

Procedure

All patients were treated with a double lumen cryoballoon (Arctic front, Cryocath, Montreal, Quebec, Canada; *Figure 1*). Both femoral veins and in some cases the left subclavian vein were used for venous access. A 10 F, intracardiac echocardiography (ICE) catheter (Flexview, EPMed) was introduced through the left femoral vein and positioned in the right atrium. A decapolar catheter was placed in the coronary sinus. After the first 10 cases, a double transseptal puncture was replaced by a single transseptal approach using a Brockenbrough needle, guided by both ICE and fluoroscopy. ICE was also used to ensure a posterior transseptal approach. A circular mapping catheter was advanced and positioned in the antrum of each PV to record the presence of PV potentials. After registration, the sheath was exchanged for a 14 F steerable sheath. The mapping catheter was exchanged for a 23 or 28 mm, 12 F balloon catheter, positioned over an exchange wire to occlude the ostium of each PV (*Figure 2*). Cryoenergy was given for 5 min per application. The applications per vein were directed towards the major side branches. Before targeting the right superior PV (RSPV), a quadripolar catheter was positioned in the superior caval vein for continuous phrenic nerve stimulation during cryoapplication. At loss of capture, the ablation was instantaneously terminated. After targeting all PVs, the cryocatheter was exchanged for the circular mapping catheter to check for remaining electrical activity. If this registration showed persistence of the PV potentials, the cryoballoon was introduced again, trying to maximize wall contact at the location of the remaining potentials (as guided by the circular catheter, ICE, and fluoroscopy). If after this second ablation attempt the activity remained present, a conventional cryocatheter (Freezor Max, Cryocath) was used to perform a segmental isolation through the same transseptal puncture. If isolation could be achieved with the balloon, the patient was categorized as 'balloon', and if additional segmental isolation had to be performed, he was categorized as 'hybrid'. These categories were included in further analysis. The day after the procedure, a transthoracic echocardiogram was made to exclude pericardial effusion and a chest X-ray to exclude pneumothorax and other thoracic complications.

All patients were treated with oral anticoagulation for at least 1 month before the procedure, aiming at an INR of 2.5–3.5. Two days before the procedure, patients were admitted and the oral anticoagulants were replaced by unfractionated heparin, aiming at a three times normal aPTT ratio. Two hours before the ablation, heparin was stopped. After venous puncture, and before transseptal puncture a 5000 IU heparin bolus was given. After transseptal puncture another 5000 IU heparin was given and a continuous titrated infusion of heparin was started. During the procedure, the activated clotting time was monitored every 30 min and kept above 350 s. After the procedure, the patients were treated with heparin and oral anticoagulants were restarted.

Anti-arrhythmic drug treatment after ablation

During the 3-month follow-up period after ablation, all patients were continued on the anti-arrhythmic medication they were taking before the ablation.

Follow-up method

Before ablation, patients were instructed to use an event recorder and to transmit daily at least one transtelephonic ECG strip at a fixed hour, and when symptoms were present. This was started 1 month before ablation and continued for 3 months afterwards. The heart rhythm on the ECG strips was coded as sinus rhythm, atrial flutter, atrial tachycardia, or AF. Atrial and ventricular premature beats and sinus tachycardia were coded, but are not reported, as they were infrequent. The heart rate during episodes of sinus rhythm was measured. Transmissions were coded as symptomatic or asymptomatic. The AF burden was defined as the percentage of days on which an AF episode was transmitted. Multislice CT scans

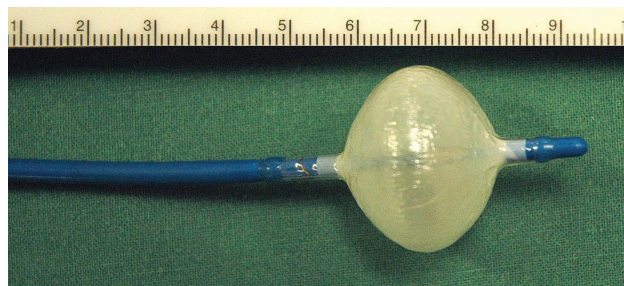


Figure 1 Distal end of a 23 mm, 10.5 F, double lumen cryoballoon catheter (Cryocath) after inflation.

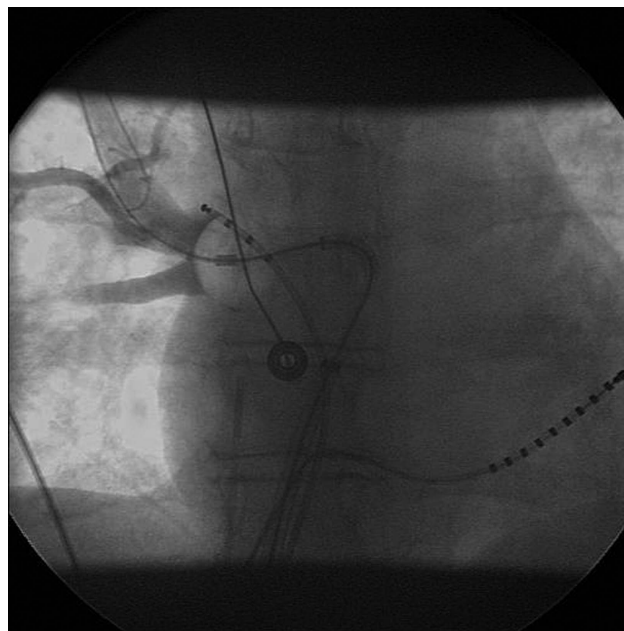


Figure 2 X-ray while contrast fluid is injected, showing occlusion of the right superior pulmonary vein with the cryoballoon catheter. Quadripolar pacing catheter in the superior vena caval-right atrial junction. Multipolar mapping catheter in the coronary sinus. In the mid-right-atrium, an intracardiac echo catheter is visible.

were made before and at 3 months after ablation to evaluate the possible occurrence of PV stenosis as described before. PV stenosis was defined as a reduction of the diameter of more than 25%. Patients were seen at the outpatient clinic after 3 months.

Statistical analysis

Continuous variables are expressed as the mean value \pm SD and were compared with the *t*-test. A χ^2 test was used for categorical variables. Non-parametric tests were used when appropriate. The learning curve was analysed in blocks of 10 patients. Data pertaining to number of applications, procedure, and fluoroscopy times were documented for each subgroup. Statistical analysis of the hypothesis that procedure time and fluoroscopy times varied significantly between groups 1–5 was performed using the one-way analysis of variance.

Results

Patient data

A total number of 57 patients (44 male, 13 female), mean age 55 ± 9 years, underwent PVI with a cryoballoon. The mean LA dimension was 43 ± 7 mm. The mean LA volume

Table 1 Pulmonary vein diameters (mm) at baseline and at 3 months

	LSPV		LIPV		RSPV		RIPV	
	T	F	T	F	T	F	T	F
Baseline (mean)	17.3	21.5	13.8	18.6	17.6	19.7	17.4	19.3
SD	3.8	3.7	3.0	2.8	2.9	2.6	2.8	2.8
3 months (mean)	17.2	21.0	14.1	18.6	17.9	20.0	17.0	19.6
SD	3.5	3.6	3.8	1.4	3.0	2.8	3.2	2.6
P-value	NS	NS	NS	NS	NS	NS	NS	NS

F, frontal plane diameter; LIPV, left inferior pulmonary vein; LSPV, left superior pulmonary vein; NS, not significant; P-value, baseline vs. 3 months; RIPV, right inferior pulmonary vein; RSPV, right superior pulmonary vein; SD, standard deviation; T, transverse plane diameter.

Table 2 Procedure and fluoroscopy times

Balloon size	Balloon isolation					Hybrid isolation				
	Procedure (P = 0.06)	Rx (NS)	Veins	Patients	%	Procedure (P = 0.06)	Rx (NS)	Veins	Patients	%
23 mm	162 ± 69	35 ± 30	52	14	88	218 ± 116	45 ± 33	16	4	12
28 mm	224 ± 130	64 ± 38	57	15	47	269 ± 76	69 ± 33	65	17	53
23 + 28 mm	258 ± 67	68 ± 26	16	4	43	274 ± 89	75 ± 30	12	3	57
Total	211 ± 108	52 ± 36	125	33	58	261 ± 83	66 ± 33	93	24	42

(calculated according to the ESC and ASE guidelines^{23,24}) was 66 ± 15 mL. Fourteen patients had previously undergone a cavotricuspid isthmus ablation for typical flutter. Three of the patients had thyroid disorders, hypertension was the underlying disease in eight, and hypertrophic obstructive cardiomyopathy in two patients. The mean PV diameters are shown in *Table 1*.

A total number of 18 patients had previously been treated with amiodarone, 10 were still on the drug at time of ablation.

At least 3 months follow-up was completed by all patients.

Procedures

During 57 procedures, registrations were made in 228 PVs, of which 220 showed PV potentials. All veins with potentials were targeted [left superior pulmonary vein (LSPV): $n = 57$, left inferior pulmonary vein (LIPV): $n = 53$, RSPV: $n = 56$, right inferior pulmonary vein (RIPV): $n = 54$], and 218 were successfully isolated. The median number of balloon applications per vein was 2 (range 1–10), LSPV 3 (1–7), LIPV 3 (1–10), RSPV 2 (1–8), and RIPV 2 (1–6). A median of 9 (range 4–18) applications were given during the entire procedure. Of the 220 veins, 185 veins could be isolated using only the balloon (84%) in 32 patients (54%). There were no differences between the different veins: LSPV 48 (84%), LIPV 43 (81%), RSPV 46 (82%), RIPV 48 (89%) (NS). In the remaining 33 veins (15%), a standard cryocatheter was used to perform additional segmental ablation with a median of 2 (1–7) applications to achieve complete electrical isolation (hybrid approach). The number of balloon applications did not significantly differ from the balloon group: 10 (5–17) (NS). In 17/57 patients (30%), only one vein had to be targeted with a median number of 2 (1–5) applications; in 5/57 patients (9%), two veins were targeted, and in 2/57 patients (4%), three veins were targeted.

When using a 23 mm cryoballoon (18 cases, 70 veins), 14 procedures (77%) and 52 veins (74%) were successful with just the balloon. With the 28 mm balloon (32 cases, 122 veins), 15 cases (47%) and 57 veins (47%) were successfully isolated. When using both balloons (seven cases, 28 veins), successful balloon isolation was achieved in four procedures (57%) and 16 veins (57%). The remaining required additional use of a conventional cryocatheter.

The average procedure time was 232 ± 100 min and the average fluoroscopy time 58 ± 35 min for the entire population (*Table 2*). Adding an additional segmental isolation did not significantly prolong fluoroscopy or procedure times.

Complications

In this series, two severe complications required prolonged hospitalization. One patient experienced a left-sided haemothorax after haemorrhage due to puncture of the left subclavian vein. Another required surgical drainage of a pericardial effusion due to perforation of the left auriculum after transeptal puncture. None of these complications were attributable to the use of the balloon catheter. There were four cases of right phrenic nerve paralysis after application in the RSPV. At loss of phrenic nerve capture, ablation was immediately stopped. Two cases recovered after cessation of cryotherapy within the procedure. One recovered after 3 months (as documented with fluoroscopic evaluation of the diaphragm movement). One persisted for more than 6 months. The persistent phrenic nerve paralysis occurred during ablation with a 28 mm balloon, the others when ablating with a 23 mm balloon deep inside the RSPV.

One patient developed sustained atypical atrial flutter at 3 months after ablation. It responded to flecainide therapy and did not recur. Two patients complained of haemoptysis within the first month after the procedure.

Analysis of the learning curve

When we compared the 50 last procedures in groups of 10, it was evident that procedure and fluoroscopy times fell significantly (*Figure 3*). Procedure time fell from 375 ± 87 to

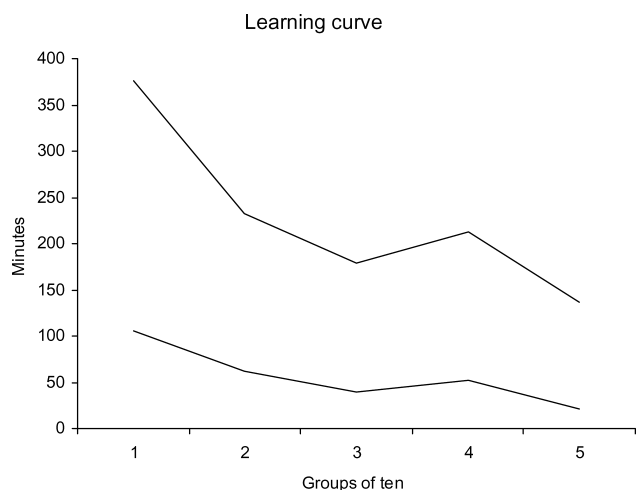


Figure 3 Procedure and fluoroscopy times (minutes) averaged per group of 10 consecutive procedures.

Table 3 Results in five consecutive groups of 10 patients

Patient number	1–10	11–20	21–30	31–40	41–50	P-value
Total number of veins	38	39	38	38	38	NS
Total number of veins with failed balloon isolation	11	7	4	4	4	NS
Total number of balloon applications	145	107	106	89	60	<0.01
Total number of conventional cryocatheter applications	18	28	10	6	15	<0.01
Patient number with additional cryoablation	5	4	4	4	4	NS

NS, not significant. P-value vs. baseline.

137 ± 40 min, fluoroscopy time from 105 ± 30 to 21 ± 7 min (both $P < 0.01$). Furthermore, the number of balloon applications decreased significantly (*Table 3*), whereas the proportion of patients requiring an additional segmental approach remained similar.

Event monitoring

All 57 patients who completed the follow-up, submitted daily rhythm strips 1 month before and 3 months after the intervention. They sent in additional strips at the time of complaints (*Table 4*). Before ablation, 981 ECG rhythm strips were available for analysis. The average heart rate in sinus rhythm was 65 ± 9 b.p.m. in the month before ablation. In the rhythm strips, AF was recorded 246 times (25%), yielding a median AF burden of 14%. After ablation, 3361 rhythm strips were transmitted and analysed. The average heart rate in sinus rhythm during the first, second, and third months was 68 ± 8 , 68 ± 9 and 66 ± 8 b.p.m., respectively. The mean heart rate differed significantly from baseline during follow-up ($P < 0.01$ for the first 2 months). Results of rhythm recordings (number of strips showing AF and calculated AF burden) are presented in *Table 4*. Overall, there was a significant reduction in AF burden from the first month on, persisting during the follow-up period. When comparing patients who experienced recurrence with the ones showing no recurrence, there was no significant difference in baseline burden: 0.29 ± 0.31 and 0.21 ± 0.32 (NS), respectively. Comparing the patients who underwent hybrid ablation with the balloon isolation patients showed no significant differences in AF burden during follow-up. The hybrid group, however, had a significant reduction in AF burden from the first month onwards, whereas the balloon group shows a clear trend in AF burden reduction during the first 2 months and becomes significant during the third month of follow-up (*Table 5*). Thirty-four (60%) patients never experienced a recurrence AF after the ablation.

Pulmonary vein diameter

All patients had multislice CT scans before and 3 months after ablation. No stenosis, as defined before, was seen at the evaluation at 3 months. Diameters are presented in *Table 1*.

Discussion

We present the data demonstrating the feasibility and efficacy of a cryoballoon in circumferential PVI. Circumferential

Table 4 Rhythm recording at baseline and during 3 months follow-up

	Baseline	1 month	2 months	3 months	Total FU
Number of recordings	981	1174	1182	1005	3361
Mean heart rate \pm SD	65 ± 9	$68 \pm 8^*$	$68 \pm 9^*$	$66 \pm 8^{**}$	
AF recordings (n)	246	108	77	45	230
Mean AF burden \pm SD	0.24 ± 0.31	$0.10 \pm 0.22^*$	$0.08 \pm 0.21^{***}$	$0.05 \pm 0.15^{***}$	0.08 ± 0.20
Median AF burden (range)	0.14 (0–1)	0 (0–0.88)	0 (0–1)	0 (0–0.80)	0 (0–1)
Patients with AF (n)	57	18	16	13	23

AF, atrial fibrillation; SD, standard deviation.

* $P < 0.01$ vs. baseline.

** $P < 0.05$ vs. baseline.

*** $P < 0.001$ vs. baseline.

Table 5 Atrial fibrillation burden

	<i>n</i>		PRE	1 M	2 M	3 M	POST
Balloon	33	Mean ± SD	0.19 ± 0.30	0.09 ± 0.23	0.08 ± 0.20	0.03 ± 0.08	0.06 ± 0.18
		Median (range)	0.06 (0–1)	0 (0–0.88)	0 (0–1)	0 (0–0.43)	0 (0–1)
		<i>P</i> -value		0.05	0.02	<0.01	<0.01
Hybrid	24	Mean ± SD	0.31 ± 0.33	0.11 ± 0.22	0.11 ± 0.23	0.09 ± 0.21	0.10 ± 0.22
		Median (range)	0.20 (0–1)	0 (0–0.75)	0 (0–0.81)	0 (0–0.80)	0 (0–0.81)
		<i>P</i> -value		<0.01	<0.01	<0.01	<0.01
Total	57	Mean ± SD	0.24 ± 0.31	0.10 ± 0.22	0.08 ± 0.21	0.05 ± 0.15	0.08 ± 0.20
		Median (range)	0.14 (0–1)	0 (0–0.88)	0 (0–1)	0 (0–0.80)	0 (0–1)
		<i>P</i> -value		<0.01	<0.01	<0.01	<0.01

1 M, first month after procedure; 2 M, second month after procedure; 3 M, third month after procedure; *n*, number; PRE, baseline; POST, 3-month total; SD, standard deviation. *P*-value vs. baseline.

RF ablation has long been shown to yield a high success rate in the treatment of patients with paroxysmal AF, yet proves to be a cumbersome endeavour with high procedure and fluoroscopy times.^{3,5} RF applications in the left atrium are associated with several complications, including substantial mortality.⁴ Previous studies have adopted cryothermia in an attempt to minimize complications since it produces homogeneous lesions and keeps the endothelium intact, with a low thrombotic potential.^{25–30} Tissue adherence during the applications limits this approach to segmental PVI.^{19,31,32}

Several authors have tried applying balloon technology with both ultrasound and high energy focused ultrasound, proving its potential for circumferential ablation, but at a high complication cost.^{33,34} Combining the relatively safe cryothermal energy with a balloon is the next step towards making circumferential isolation of the PVs a simple and safe technique. After its feasibility had been proved in animal experiments,^{20,21} we are now publishing the first human data in this field.

Acute success

Our data show a high feasibility in obtaining complete PVI with the cryoballoon, but also show that in a number of cases this seems impossible and additional conventional cryocatheter ablation is required. We believe that anatomical features are the main reason for this. Some patients had oval or slit-like-shaped PV ostia and/or veins inserting onto the left atrium with a sharp angulation. In our experience, it posed more difficulties to occlude these veins with a spherical-shaped balloon. Although without reporting this, complete occlusion seems crucial in obtaining electrical isolation. We think that lack of blood flow allows the balloon to obtain lower temperatures. Incomplete occlusion, and blood flow warming the surface of the balloon, could produce reversible lesions.^{35–37} The learning curve also shows that over time the number of balloon applications falls, indicating that operator-dependent factors were present, along with simultaneous technical improvements of the device. The fact remains, however, that the lengthy cryoapplications add to the duration of the procedure and the use of an additional conventional catheter for a hybrid approach increases the cost of the overall procedure.

Complications using cryoenergy

The most frequently seen complication in our series was phrenic nerve paralysis. This was also the major limitation in balloon catheters using different energy sources.^{33,34} Recently, it has been reported that this condition is temporary in the majority of the cases.³⁸ Stimulating the phrenic nerve with superior caval vein pacing has proven to be a valuable precaution during isolation of the right superior vein in our series. The reversibility of lesions with short cryoenergy applications remains to be proven at this site. All but one of the phrenic nerve paralysis were seen while ablating with a 23 mm balloon deep inside the RSPV, and therefore we advise caution when using this balloon size in that region.

Outcome data

An intensive follow-up, aimed at detecting asymptomatic recurrence, shows 60% freedom of AF. Several authors consider the first 3 months a blanking period in which recurrence is common, while the effect of the procedure is delayed.^{39–41} To our knowledge, this has never been proven for transvenous catheter ablation of AF, and certainly not when using cryothermal energy. Moreover, there are reports that early recurrence after RF ablation is indicative of long-term failure.⁴²

Limitations

In our series, patients received anti-arrhythmic drugs before and after the procedure, which could be regarded as a limitation of the study. However, all of the patients had documented episodes of AF while taking their anti-arrhythmic drugs before ablation. Continuing the drug therapy can be considered as a way to reduce a potential bias due to changes in pharmacological treatment. The fact that the heart rate at month 3 was comparable to the baseline value underscores that the baseline autonomic situation was present again, without a change in AF occurrence vs. month 1 and 2. We are currently continuing our long-term follow-up with cessation of anti-arrhythmic drugs in patients who are free of AF after 3 months to further examine the recurrence rate in this group.

Conclusion

We consider cryoablation with a balloon as a feasible initial approach for patients presenting with paroxysmal AF. The technique has an acceptable learning curve. The most frequent complication is phrenic nerve paralysis when ablating the RSPV, but this proved to be reversible in some of the cases.

Acknowledgements

Osama Soliman, MD, who was helpful in analysing left atrial volume data.

Conflict of interest: none declared.

References

- Fisher JD, Spinelli MA, Mookherjee D, Krumerman AK, Palma EC. Atrial fibrillation ablation: reaching the mainstream. *Pacing Clin Electrophysiol* 2006;**29**:523–537.
- Haissaguerre M, Jais P, Shah DC, Takahashi A, Hocini M, Quiniou G, Garrigue S, Le Mouroux A, Le Metayer P, Clementy J. Spontaneous initiation of atrial fibrillation by ectopic beats originating in the pulmonary veins. *N Engl J Med* 1998;**339**:659–666.
- Pappone C, Oreto G, Rosanio S, Vicedomini G, Tocchi M, Gugliotta F, Salvati A, Dicandia C, Calabro MP, Mazzone P, Ficarra E, Di Gioia C, Gulletta S, Nardi S, Santinelli V, Benussi S, Alfieri O. Atrial electroanatomic remodeling after circumferential radiofrequency pulmonary vein ablation: efficacy of an anatomic approach in a large cohort of patients with atrial fibrillation. *Circulation* 2001;**104**:2539–2544.
- Cappato R, Calkins H, Chen SA, Davies W, Lesaka Y, Kalman J, Kim YH, Klein G, Packer D, Skanes A. Worldwide survey on the methods, efficacy, and safety of catheter ablation for human atrial fibrillation. *Circulation* 2005;**111**:1100–1105.
- Marrouche NF, Dresing T, Cole C, Bash D, Saad E, Balaban K, Pavia SV, Schweikert R, Saliba W, Abdul-Karim A, Pisano E, Fanelli R, Tchou P, Natale A. Circular mapping and ablation of the pulmonary vein for treatment of atrial fibrillation: impact of different catheter technologies. *J Am Coll Cardiol* 2002;**40**:464–474.
- Lin WS, Tai CT, Hsieh MH, Tsai CF, Lin YK, Tsao HM, Huang JL, Yu WC, Yang SP, Ding YA, Chang MS, Chen SA. Catheter ablation of paroxysmal atrial fibrillation initiated by non-pulmonary vein ectopy. *Circulation* 2003;**107**:3176–3183.
- Oral H, Scharf C, Chugh A, Hall B, Cheung P, Good E, Veerareddy S, Pelosi F Jr, Morady F. Catheter ablation for paroxysmal atrial fibrillation: segmental pulmonary vein ostial ablation versus left atrial ablation. *Circulation* 2003;**108**:2355–2360.
- Pappone C, Manguso F, Vicedomini G, Gugliotta F, Santinelli O, Ferro A, Gulletta S, Sala S, Sora N, Paglino G, Augello G, Agricola E, Zangrillo A, Alfieri O, Santinelli V. Prevention of iatrogenic atrial tachycardia after ablation of atrial fibrillation: a prospective randomized study comparing circumferential pulmonary vein ablation with a modified approach. *Circulation* 2004;**110**:3036–3042.
- Rotter M, Takahashi Y, Sanders P, Haissaguerre M, Jais P, Hsu LF, Sacher F, Pasquie JL, Clementy J, Hocini M. Reduction of fluoroscopy exposure and procedure duration during ablation of atrial fibrillation using a novel anatomical navigation system. *Eur Heart J* 2005;**26**:1415–1421.
- Wazni OM, Rossillo A, Marrouche NF, Saad EB, Martin DO, Bhargava M, Bash D, Beheiry S, Wexman M, Potenza D, Pisano E, Fanelli R, Bonso A, Themistoclakis S, Rციეძი D, Saliba W, Schweikert RA, Brachmann J, Raviele A, Natale A. Embolic events and char formation during pulmonary vein isolation in patients with atrial fibrillation: impact of different anticoagulation regimens and importance of intracardiac echo imaging. *J Cardiovasc Electrophysiol* 2005;**16**:576–581.
- Tamborero D, Mont L, Nava S, de Caralt TM, Molina I, Scalise A, Perea RJ, Bartholomay E, Berruezo A, Matiello M, Brugada J. Incidence of pulmonary vein stenosis in patients submitted to atrial fibrillation ablation: a comparison of the Selective Segmental Ostial Ablation vs. the Circumferential Pulmonary Veins Ablation. *J Interv Card Electrophysiol* 2005;**14**: 21–25.
- Saad EB, Marrouche NF, Saad CP, Ha E, Bash D, White RD, Rhodes J, Prieto L, Martin DO, Saliba W, Schweikert RA, Natale A. Pulmonary vein stenosis after catheter ablation of atrial fibrillation: emergence of a new clinical syndrome. *Ann Intern Med* 2003;**138**:634–638.
- Sonmez B, Demirsoy E, Yagan N, Unal M, Arbatli H, Sener D, Baran T, Ilkova F. A fatal complication due to radiofrequency ablation for atrial fibrillation: atrio-esophageal fistula. *Ann Thorac Surg* 2003;**76**:281–283.
- Doll N, Borger MA, Fabricius A, Stephan S, Gummert J, Mohr FW, Hauss J, Kottkamp H, Hindricks G. Esophageal perforation during left atrial radiofrequency ablation: Is the risk too high? *J Thorac Cardiovasc Surg* 2003;**125**:836–842.
- Gillinov AM, Pettersson G, Rice TW. Esophageal injury during radiofrequency ablation for atrial fibrillation. *J Thorac Cardiovasc Surg* 2001;**122**:1239–1240.
- Pappone C, Oral H, Santinelli V, Vicedomini G, Lang CC, Manguso F, Torracca L, Benussi S, Alfieri O, Hong R, Lau W, Hirata K, Shikuma N, Hall B, Morady F. Atrio-esophageal fistula as a complication of percutaneous transcatheter ablation of atrial fibrillation. *Circulation* 2004;**109**:2724–2726.
- Scanavacca MI, D'Avila A, Parga J, Sosa E. Left atrial-esophageal fistula following radiofrequency catheter ablation of atrial fibrillation. *J Cardiovasc Electrophysiol* 2004;**15**:960–962.
- Jais P, Sanders P, Hsu LF, Hocini M, Sacher F, Takahashi Y, Rotter M, Rostock T, Bordachar P, Reuter S, Laborderie J, Clementy J, Haissaguerre M. Flutter localized to the anterior left atrium after catheter ablation of atrial fibrillation. *J Cardiovasc Electrophysiol* 2006;**17**: 279–285.
- Tse HF, Reek S, Timmermans C, Lee KL, Geller JC, Rodriguez LM, Ghaye B, Ayers GM, Crijns HJ, Klein HU, Lau CP. Pulmonary vein isolation using transvenous catheter cryoablation for treatment of atrial fibrillation without risk of pulmonary vein stenosis. *J Am Coll Cardiol* 2003;**42**: 752–758.
- Sarabanda AV, Bunch TJ, Johnson SB, Mahapatra S, Milton MA, Leite LR, Bruce GK, Packer DL. Efficacy and safety of circumferential pulmonary vein isolation using a novel cryothermal balloon ablation system. *J Am Coll Cardiol* 2005;**46**:1902–1912.
- Garan A, Al-Ahmad A, Mihalik T, Cartier C, Capuano L, Holtan D, Song C, Homoud MK, Link MS, Estes NA 3rd, Wang PJ. Cryoablation of the pulmonary veins using a novel balloon catheter. *J Interv Card Electrophysiol* 2006;**15**:79–81.
- Scholten MF, Thornton AS, Mekel JM, Jordaens LJ. Targets and endpoints in ablation therapy for atrial fibrillation in the light of pathophysiological mechanisms. *J Interv Card Electrophysiol* 2006;**15**:27–33.
- Lang RM, Bierig M, Devereux RB, Flachskampf FA, Foster E, Pellikka PA, Picard MH, Roman MJ, Seward J, Shanewise JS, Solomon SD, Spencer KT, Sutton MS, Stewart WJ. Recommendations for chamber quantification: a report from the American Society of Echocardiography's Guidelines and Standards Committee and the Chamber Quantification Writing Group, developed in conjunction with the European Association of Echocardiography, a branch of the European Society of Cardiology. *J Am Soc Echocardiogr* 2005;**18**:1440–1463.
- Khankirawatana B, Khankirawatana S, Porter T. How should left atrial size be reported? Comparative assessment with use of multiple echocardiographic methods. *Am Heart J* 2004;**147**:369–374.
- Rodriguez LM, Leunissen J, Hoekstra A, Korteling BJ, Smeets JL, Timmermans C, Vos M, Daemen M, Wellens HJ. Transvenous cold mapping and cryoablation of the AV node in dogs: observations of chronic lesions and comparison to those obtained using radiofrequency ablation. *J Cardiovasc Electrophysiol* 1998;**9**:1055–1061.
- Hunt GB, Chard RB, Johnson DC, Ross DL. Comparison of early and late dimensions and arrhythmogenicity of cryolesions in the normothermic canine heart. *J Thorac Cardiovasc Surg* 1989;**97**:313–318.
- Wetstein L, Mark R, Kaplan A, Mitamura H, Sauermelech C, Michelson EL. Nonarrhythmogenicity of therapeutic cryothermic lesions of the myocardium. *J Surg Res* 1985;**39**:543–554.
- Wadhwa MK, Rahme MM, Dobak J, Li H, Wolf P, Chen P, Feld GK. Transcatheter cryoablation of ventricular myocardium in dogs. *J Interv Card Electrophysiol* 2000;**4**:537–545.
- Khairy P, Chauvet P, Lehmann J, Lambert J, Macle L, Tanguay JF, Sirois MG, Santoianni D, Dubuc M. Lower incidence of thrombus formation with cryoenergy versus radiofrequency catheter ablation. *Circulation* 2003;**107**:2045–2050.
- van Oeveren W, Crijns HJ, Korteling BJ, Wegereef EW, Haan J, Tigchelaar I, Hoekstra A. Blood damage, platelet and clotting activation during application of radiofrequency or cryoablation catheters: a comparative in vitro study. *J Med Eng Technol* 1999;**23**:20–25.

31. Wong T, Markides V, Peters NS, Davies DW. Percutaneous pulmonary vein cryoablation to treat atrial fibrillation. *J Interv Card Electrophysiol* 2004; **11**:117-126.
32. Scholten MF, Kimman GJ, Janse PA, Thornton AS, Theuns DAMJ, Jordaens LJ. Electrical Isolation of pulmonary veins using cryothermal energy: study design and initial results. *Neth Heart J* 2003;453-458.
33. Natale A, Pisano E, Shewchik J, Bash D, Fanelli R, Potenza D, Santarelli P, Schweikert R, White R, Saliba W, Kanagaratnam L, Tchou P, Lesh M. First human experience with pulmonary vein isolation using a through-the-balloon circumferential ultrasound ablation system for recurrent atrial fibrillation. *Circulation* 2000; **102**:1879-1882.
34. Antz M, Chun KR, Ouyang F, Kuck KH. Ablation of atrial fibrillation in humans using a balloon-based ablation system: identification of the site of phrenic nerve damage using pacing maneuvers and CARTO. *J Cardiovasc Electrophysiol* 2006; **17**:1242-1245.
35. Theuns DA, Kimman GP, Szili-Torok T, Res JC, Jordaens LJ. Ice mapping during cryothermal ablation of accessory pathways in WPW: the role of the temperature time constant. *Europace* 2004; **6**:116-122.
36. Camm J, Ward DE, Spurrell RA, Rees GM. Cryothermal mapping and cryoablation in the treatment of refractory cardiac arrhythmias. *Circulation* 1980; **62**:67-74.
37. Dubuc M, Roy D, Thibault B, Ducharme A, Tardif JC, Villemaire C, Leung TK, Talajic M. Transvenous catheter ice mapping and cryoablation of the atrioventricular node in dogs. *Pacing Clin Electrophysiol* 1999; **22**: 1488-1498.
38. Sacher F, Monahan KH, Thomas SP, Davidson N, Adragao P, Sanders P, Hocini M, Takahashi Y, Rotter M, Rostock T, Hsu LF, Clementy J, Haissaguerre M, Ross DL, Packer DL, Jais P. Phrenic nerve injury after atrial fibrillation catheter ablation: characterization and outcome in a multicenter study. *J Am Coll Cardiol* 2006; **47**:2498-2503.
39. Bertaglia E, Stabile G, Senatore G, Zoppo F, Turco P, Amellone C, De Simone A, Fazzari M, Pascotto P. Predictive value of early atrial tachyarrhythmias recurrence after circumferential anatomical pulmonary vein ablation. *Pacing Clin Electrophysiol* 2005; **28**:366-371.
40. O'Donnell D, Furniss SS, Dunuwille A, Bourke JP. Delayed cure despite early recurrence after pulmonary vein isolation for atrial fibrillation. *Am J Cardiol* 2003; **91**:83-85.
41. Oral H, Knight BP, Ozaydin M, Tada H, Chugh A, Hassan S, Scharf C, Lai SW, Greenstein R, Pelosi F Jr, Strickberger SA, Morady F. Clinical significance of early recurrences of atrial fibrillation after pulmonary vein isolation. *J Am Coll Cardiol* 2002; **40**:100-104.
42. Cheema A, Vasamreddy CR, Dalal D, Marine JE, Dong J, Henrikson CA, Spragg D, Cheng A, Nazarian S, Sinha S, Halperin H, Berger R, Calkins H. Long-term single procedure efficacy of catheter ablation of atrial fibrillation. *J Interv Card Electrophysiol* 2006; **15**:145-155.