



**Circumferential Pulmonary Vein Isolation With the Cryoballoon Technique:
Results From a Prospective 3-Center Study**

Thomas Neumann, Jürgen Vogt, Burghard Schumacher, Anja Dorszewski, Malte Kuniss, Hans Neuser, Klaus Kurzidim, Alexander Berkowitsch, Marcus Koller, Johannes Heintze, Ursula Scholz, Ulrike Wetzel, Michael A.E. Schneider, Dieter Horstkotte, Christian W. Hamm, and Heinz-Friedrich Pitschner

J. Am. Coll. Cardiol. 2008;52;273-278

doi:10.1016/j.jacc.2008.04.021

This information is current as of July 16, 2008

The online version of this article, along with updated information and services, is located on the World Wide Web at:

<http://content.onlinejacc.org/cgi/content/full/52/4/273>



Circumferential Pulmonary Vein Isolation With the Cryoballoon Technique

Results From a Prospective 3-Center Study

Thomas Neumann, MD,* Jürgen Vogt, MD,† Burghard Schumacher, MD,‡ Anja Dorszewski, MD,† Malte Kuniss, MD,* Hans Neuser, MD,‡ Klaus Kurzidim, MD,* Alexander Berkowitsch, PhD,* Marcus Koller, MD,‡ Johannes Heintze, MD,† Ursula Scholz, MD,† Ulrike Wetzels, MD,† Michael A. E. Schneider, MD,‡ Dieter Horstkotte, MD, PhD, FESC, FACC,† Christian W. Hamm, MD, FESC,* Heinz-Friedrich Pitschner, MD, FESC*
Bad Nauheim, Bad Oeynhausen, and Bad Neustadt/Saale, Germany

Objectives	The purpose of this study was to investigate the efficacy safety of the novel cryoballoon device (Arctic Front, Cryocath, Quebec, Canada).
Background	Antral pulmonary vein (PV) ablation with radiofrequency energy is widely used as a strategy for catheter ablation of paroxysmal atrial fibrillation (PAF). A novel double lumen cryoballoon catheter was designed for circumferential pulmonary vein isolation (PVI) with the cryoablation technique.
Methods	We consecutively enrolled 346 patients with symptomatic, drug refractory paroxysmal (n = 293) or persistent (n = 53) atrial fibrillation (AF). In all patients, PVI of all targeted PVs was the therapeutic aim. The primary end points of this nonrandomized study were: 1) acute isolation rate of targeted PV; and 2) first electrocardiogram-documented recurrence of AF. The secondary end point was occurrence of PV stenosis or atrio-esophageal fistula.
Results	The 1,360 of 1,403 PVs (97%) were targeted with balloons or balloons in combination with the use of Freezor Max (Cryocath). We found that ablation with the cryoballoon resulted in maintenance of sinus rhythm in 74% of patients with PAF and 42% of patients with persistent AF. No PV narrowing occurred. The most frequent complication was right phrenic nerve palsy observed during cryoballoon ablation at the right superior PV.
Conclusions	Pulmonary vein isolation with a new cryoballoon technique is feasible. Sinus rhythm can be maintained in the majority of patients with PAF by circumferential PVI using a cryoballoon ablation system. Cryoablation was less effective in patients with persistent AF than in patients with PAF. (J Am Coll Cardiol 2008;52:273-8) © 2008 by the American College of Cardiology Foundation

Given limited success rates of drug therapy for atrial fibrillation (AF), interventional treatment options have been developed during the last decade (1). Catheter ablation of AF has been established as an important therapeutic strategy. It is recommended as second-line therapy in patients with symptomatic AF (2).

The cornerstone of catheter ablation for AF is electrical isolation of the pulmonary veins (PVs). New technical developments have been used in order to simplify pulmonary vein isolation (PVI) and to reduce the procedure time by using an anatomically based ablation approach. Catheters designed as balloons might be more effective and safe to use for circumferential ablation (3-5). The purpose of the present study was to investigate the effectiveness and the safety of a novel cryoballoon device (Arctic Front, Cryocath, Quebec, Canada).

Methods

Patients. The study enrolled 346 consecutive patients with symptomatic and drug refractory paroxysmal or persistent AF. In all patients, AF was documented at least on separate electrocardiograms (ECGs) within the last 3 months

From the *Department of Cardiology, Kerckhoff Heart Center, Bad Nauheim, Germany; †Department of Cardiology, Heart and Diabetes Center North Rhine-Westphalia, Ruhr University Bochum, Bad Oeynhausen, Germany; and the ‡Department of Cardiology, Center of Cardiovascular Medicine, Bad Neustadt/Saale, Germany. Dr. Vogt has received speakers' honoraria and honoraria for advisory board meetings from Cryocath; Dr. Schumacher has been on the Speakers' Bureau of Cryocath; Dr. Kuniss has received speakers' honoraria from Cryocath; Dr. Heintze has received honoraria for cryo training from Cryocath; and Dr. Pitschner has received honoraria for advisory board meetings from Cryocath.

Manuscript received January 15, 2008; revised manuscript received March 12, 2008, accepted April 3, 2008.

**Abbreviations
and Acronyms**

AF = atrial fibrillation
LA = left atrium/atrial
MRI = magnetic resonance imaging
PAF = paroxysmal atrial fibrillation
PNP = phrenic nerve palsy
PV = pulmonary vein
PVI = pulmonary vein isolation

before ablation. Exclusion criteria were defined as advanced structural heart disease including moderate-to-severe valvular stenosis or insufficiency, previous myocardial infarction, congenital heart disease, left ventricular ejection fraction <45%, coronary artery bypass graft surgery within the last 3 months, chronic obstructive pulmonary disease treated with beta-sympathomimetic drugs, severe respiratory insufficiency, known bleeding diathesis or intolerance of heparin or oral anticoagulation, attempted AF ablation in the past, left atrial (LA) thrombus, pregnancy, and severe comorbidity.

Pre-ablation. Medical history was obtained during the clinic visit and a review of the medical records including ECGs and Holter ECG recordings showing episodes of AF. The risk of ablation was discussed in detail, and all patients gave written informed consent before the procedure. The study was approved by the local institutional ethics committee. Three days before intervention, coumadin was stopped and replaced by subcutaneous low-molecular-weight heparin. All antiarrhythmic drugs including amiodarone were discontinued at least 3 days before ablation. Beta-blockers were allowed according to the protocol. All patients underwent transthoracic echocardiography to determine LA diameter. To assess PV size and geometry, magnetic resonance imaging (MRI) or computer tomography images were obtained before intervention.

Interventions. Procedures were performed under conscious sedation and analgesia with appropriate doses of midazolam and dipidolor. During the catheter procedure, an infusion of heparin was maintained to achieve an activated clotting time >300 s. Measurements were performed every 30 min routinely.

A diagnostic quadripolar catheter (Biosense Webster Inc., Diamond Bar, California) was positioned in the coronary sinus for stimulation of the LA. The LA was accessed via the transseptal route from the right femoral vein with a steerable 12-F sheath (FlexCath, Cryocath) to guide a double walled cryoballoon (Arctic Front, Cryocath) over the wire (Emerald guidewire 0.32-F, Cordis, Johnson & Johnson, Diamond Bar, California). A second transseptally introduced 8-F sheath (Fast Cath, SJM, Minnetonka, Minnesota) was used for placement of a multipolar Lasso catheter (Biosense Webster) into the LA to map signals before and after ablation at the ostial sides of PVs. After angiography in the left anterior oblique 60° and right anterior oblique 30° or anterior-posterior projections, each PV was mapped. With different sizes of Lasso catheters (Biosense Webster), we mapped inside the PVs (15-mm Lasso catheter) and outside at the level of PV antrum (20- to 25-mm Lasso catheters). In 34 cases we assessed immediate

success of ablation with the NavX system (Endocardial Solutions, St. Jude Medical, Inc., St. Paul, Minnesota). Complete isolation was verified as a reduction of all signals ≤ 0.2 mV. Exit block from the vein was confirmed by pacing at the location of bipolar signals within the PV ostium in all patients. During sinus rhythm, cryoballoon ablation was performed after mapping the areas of interest distal to the antrum. During AF, the transition zone was defined primarily by anatomical orientation, since the cryoballoon itself does not have any electrodes for recording of local electrical signals.

There are currently 2 sizes of balloon catheters available (23 or 28 mm). Before the ablation procedure, the diameters of the PVs were determined by computed tomography/MRI scan. The balloon size was selected accordingly. With the deflated balloon catheter inside the sheath, a guidewire was placed in one of the PV branches. The balloon was then advanced towards the PV ostium and inflated. The degree of balloon occlusion obtained by injection of 50% diluted contrast medium into the PV was judged using a semiquantitative grading: grade 4 = excellent (full retention of contrast medium without visible outflow) to grade 1 = very poor (immediate rapid outflow from the PV). We aimed for at least 1 cryoballoon ablation with occlusion of grade 4 on every targeted PV. Additional delivery of cryoenergy was applied after the guidewire was placed in different branches of the PV with early branching, which usually allowed for better contact of the balloon at different sites of the PV antrum.

Based on the animal data (6), we chose an application time of 240 to 360 s per freeze. Balloon temperature was measured at the proximal end of the balloon where the vaporized N₂O was sucked back into the console.

During cryoablation of the antrum of the right-sided PVs, unaffected phrenic movement was monitored by either continuous phrenic nerve stimulation via a right atrial stimulation catheter or by continuous monitoring of spontaneous breathing. In all patients, PVI of all targeted PVs was the therapeutic aim with the primary use of a cryoballoon only. An observation period after isolation to check for recurrence of conduction was 20 min. If a PV could not be reached with a cryoballoon or no isolation could be achieved after 5 applications with any balloon, an 8-mm tip cryoablation catheter (Freezor Max, Cryocath) was used to finish PVI with signal control at the Lasso catheter.

Post-ablation management. Intravenous heparin was continued to achieve a partial thromboplastin time of 50 to 70 s. Between post-interventional days 2 and 5, a 24- to 48-h Holter ECG was obtained in every patient. Before hospital discharge, all patients underwent transthoracic echocardiography to exclude pericardial effusion and chest X-ray to document adequate phrenic movement.

Oral anticoagulation with coumadin was started 1 day after PVI, targeting an international normalized ratio of 2.0 to 3.0 for at least 3 months. During a blanking period of 3 months, antiarrhythmic treatment was allowed even in

asymptomatic patients to facilitate maintenance of sinus rhythm. Antiarrhythmic drugs were stopped after 3 months in the majority of patients. Antiarrhythmic drug therapy was continued only in patients with ongoing highly symptomatic episodes of AF beyond 3 months after intervention. **Follow-up.** After discharge from the hospital, patients were scheduled for quarterly follow-up visits. Late follow-up (>1 year post-intervention) was performed once a year. Seven-day Holter ECG recordings were obtained at each follow-up visit. Patients without documented AF during follow-up who received antiarrhythmic drug therapy with amiodarone or class I antiarrhythmic agents at the discretion of their physician (n = 5) were excluded from the analysis of the second primary end point. The main reason for this intermittent drug therapy was premature beats. During a follow up of 3 to 12 months, at least 1 MRI/computed tomography scan was performed to assess PV diameters and to exclude PV stenosis.

Study end points. The primary end points of this nonrandomized study were: 1) acute isolation rate of targeted PV; and 2) first ECG documented recurrence of AF after a blanking period of 3 months in the absence of any antiarrhythmic drug therapy. The secondary end point was the occurrence of PV stenosis or atrio-esophageal fistula and peri-interventional safety.

Statistical analysis. For statistical analysis, Kaplan-Meier univariate analysis and a multivariate Cox regression model were used to estimate AF-free survival. All continuous variables were tested on normality using the Kolmogorov-Smirnov test. Normal distributed variables were analyzed using a paired and unpaired *t* test (2 groups analysis) and analysis of variance (N groups analysis). In the case of nonnormal distribution, continuous variables were analyzed using the Wilcoxon matched pairs test/Mann-Whitney U test (2 groups analysis) and Kruskal-Wallis H test/Friedman test (N groups analysis). Continuous data were described in median, lowest (Q25), and highest (Q75) quartiles.

Results

Patients. In total, 346 consecutive patients were treated with circumferential antral PVI using a new cryoballoon catheter. Clinical characteristics are given in Table 1.

Procedural characteristics. The median total procedure time was 170 (interquartile range 25/75 = 140 to 195) min. The median fluoroscopy time was 40 (30 to 57) min. Total cryoablation time was 46 (26 to 60) min/patient. Time of applications per freeze was 300 (range 28 to 480) s with a median number of applications 11 (9 to 13). The median number of cryoballoon applications per PV was 2.8 (2.3 to 3.4). Early discontinuation of an application was mainly due to right phrenic nerve palsy (PNP) detected by deep breathing or stimulation of the right phrenic nerve during ablation of the right superior PV.

A total of 1,360 of 1,403 PVs (97%) could be isolated with 1 or 2 balloons, or balloons in combination with the

	Paroxysmal AF (n = 293)	Persistent AF (n = 53)	p Value
Gender, male/female	173/120	41/12	NS
Age, yrs	59 (51-65)	59 (52-66)	NS
Duration of AF, yrs	6.5 (5.3-7.5)	7.7 (5.6-8.7)	NS
Number of unsuccessful antiarrhythmic drug therapies			
n ≥ 3	100	21	NS
n < 3	193	32	NS
Left atrial diameter			
Short axis, mm	40 (37-42)	42 (40-44)	<0.001
Long axis, mm	52 (48-56)	57 (52-59)	<0.001
Left ventricular ejection fraction, %	60 (60-60)	60 (55-60)	NS
Hypertension	129	25	NS
Other mild heart disease	42	16	0.01

Numbers are counts and the continuous data were described in median, lowest (interquartile range 25), and highest (interquartile range 175) quartiles. AF = atrial fibrillation.

use of Freezor Max (Cryocath) in 58 patients. Fourteen patients had a common ostium of the left-sided PV, and a right-sided accessory PV was observed in 5 patients. In 109 PVs, the use of Freezor Max was required with a distribution as follows: left superior PV, n = 24; left inferior PV, n = 21; right superior PV, n = 28; right inferior PV, n = 36. The median number of cryo applications with the Freezor Max was 3 (2 to 5) per PV. In 116 patients, small balloons were initially selected. In 230 patients, the procedure was started with a 28-mm balloon. We observed no significant differences in the number of cryoballoon applications, total cryo time per PV, procedure time, the incidence of acute PV isolation between a 23-mm balloon and a 28-mm balloon, and long-term success. The fluoroscopy time was significantly higher with 28-mm balloons versus 23-mm balloons (median fluoroscopy time 46 min vs. 33 min).

At least 1 cryoenergy application with grade 4 occlusion in every targeted PV could be achieved in 90% of the PVs. Thirty-three patients (9.5%) needed more than 1 size of cryoablation balloon for PVI. The initial degree of vein occlusion in these cases was mostly 3 and sometimes grade 2, but none of these cases had an occlusion grade of 4. In 6 of these 33 patients, the combination 23-mm balloon and 28-mm balloon and cryotip catheter were used for PVI. In the case of an ECG document with typical flutter, we additionally performed a right atrial isthmus block (n = 26 patients).

Follow-up results. Median follow-up was 12 (7 to 16) months; in 264 patients follow-up was ≥6 months, and in 133 patients follow-up was more than 12 months. Of 346 patients (Table 1), 55 did not exceed the blanking period and were only available for analysis of acute results. In 4 patients, the Holter times were too short or it was not possible to analyze because of artefacts in the Holter. A further 9 patients were lost in follow-up without information where they could be reached. Fourteen patients refused further follow-up visits. None of the patients that we could

reach by telephone contact underwent a further radiofrequency ablation due to recurrence. The 14 patients who refused further follow-up visits were free of symptomatic arrhythmias evaluated by telephone interview. Repeat ablation was performed in 35 patients. These patients were counted as “failures” because they had reached the primary end point of recurrence of AF.

Freedom from documented paroxysmal and persistent AF-free survival is given in Figure 1. We found that circumferential PVI with the cryoballoon technique resulted in maintenance of sinus rhythm without the use of antiarrhythmic drug therapy in 159 (74%) patients with paroxysmal atrial fibrillation (PAF). In total, in 41 patients antiarrhythmic drug therapy with amiodarone or class I agents were not discontinued at the time of 3 months follow-up. Maintenance of sinus rhythm without the need for antiarrhythmic drug therapy was observed in only 13 of 31 patients (42%) with persistent AF.

The multivariate Cox regression model revealed that persistent AF and long axis of the LA (evaluated by echocardiography) >60 mm were independent predictors of documented recurrence after adjustment for other clinical variables including gender, age, hypertension, mild heart disease, left ventricular ejection fraction, and LA diameter. As PV diameters may change on different occasions, a reduction of >30% was set as a potential procedure-related narrowing, which was not observed in any patient. In 310 patients, MRI was performed to measure PV diameters before ablation. Data on 1,222 PVs were available. Measurements were done as described elsewhere (7). The median (interquartile range 25/interquartile range 75) diameters of left superior PV, left inferior PV, right superior PV, and right inferior PV were 18 (16 to 21), 17 (16 to 18), 20 (17 to 21.5), and 18 (16 to 20) mm in the large axis of

mostly oval-shaped PV. During follow-up, PV measurements of 239 patients were available. No stenosis or a diameter reduction >30% was observed.

Complications. Early periprocedural complications (2 pericardial tamponades) were observed and treated with pericardial drainage; both resolved without the need for surgery. We observed 5 patients with groin hematoma, no patients with retroperitoneal bleeding, 2 patients with femoral arterial pseudoaneurysm, and 1 patient with femoral arteriovenous fistula. All of these cases with vascular complications could be managed conservatively.

In 26 of 346 patients, right PNP was observed during cryoablation of the right superior PV. In 24 of 26 patients, PNP occurred when using a 23-mm balloon. Only in 2 patients was PNP related to cryoablation with a 28-mm balloon. Two of the 26 PNP cases resolved during the procedure. An early termination of cryoenergy application during right phrenic pacing did not prevent the subsequent occurrence of PNP. In all patients, full recovery of right phrenic function was observed during follow-up of less than 1 year. In 2 patients, transient ST-segment elevation because of bubbles inside of the sheath occurred in the inferior leads without hemodynamic compromise. It resolved within <2 min in both patients. We additionally observed 2 patients (0.8%) with LA flutter occurring within 3 months after the intervention. These 2 patients were not included in the subsequent analysis of long-term successful ablation. Both cases successfully resolved with a further LA ablation procedure. We observed no other atrial tachycardia or atrial flutter during follow-up. No patients developed an atrioesophageal fistula, stroke, death, or other peri-interventional complication.

Discussion

The emerging need for better safety and facilitation of catheter ablation for AF has recently been emphasized in different expert consensus statements (Heart Rhythm Society/European Heart Rhythm Association/European Cardiac Arrhythmia Society/American College of Cardiology/American Heart Association) (8,9). Novel technologies including high-intensity focused ultrasound, laser ablation, and the cryoablation technique are currently under investigation (3,10-13). We found that circumferential PVI with the cryoballoon technique resulted in maintenance of sinus rhythm without the use of antiarrhythmic drug therapy in 74% of patients with PAF. In patients with persistent AF, cryoballoon ablation was less effective.

Main findings in comparison with those of previous studies. Our study demonstrates that PVI using the cryoballoon technique is effective in PAF independently of the antiarrhythmic drug use. We documented that the patients remained free from AF by means of serial Holter ECG recording including the use of a 7-day event recorder throughout follow-up. Comparison of these results with other published PVI studies using radiofrequency energy

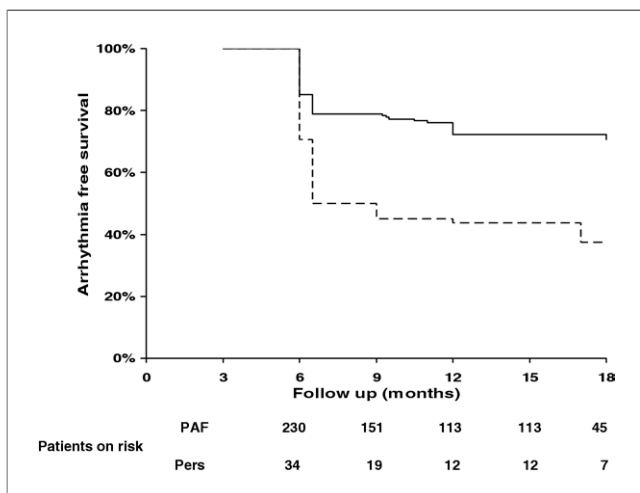


Figure 1 PAF Versus Persistent AF

Kaplan-Meier curves of electrocardiogram-documented paroxysmal (PAF) (continuous line) and persistent (Pers) (dashed line) atrial fibrillation (AF)-free survival after pulmonary vein isolation with a blanking period of 3 months.

might be impeded because of different follow-up considerations and different definitions of the study end points (14-20). We used: 1) serial 7-day Holter ECG monitoring; 2) a strong end point (documented AF relapses); 3) the single procedure success rate without creation of additional linear lesions; and 4) Kaplan-Meier analysis to report outcome and not freedom from AF on a monthly basis. Comparable radiofrequency ablation studies based on the "patients' clinical characteristics" demonstrated single procedure efficacy of 42% to 88%. Particularly with regard to the studies with a better outcome, they mostly used a combined ablation strategy with PVI and additional substrate modification (ablation of complex electrograms, mitral isthmus line, posterior LA line) (14,19,20).

The recently published early results after PVI using the cryoballoon system in 57 patients with PAF by Jordaens *et al.* (11) are comparable to our study. This group demonstrated acute success rates, complications, and outcome from a short-term follow-up of 3 months. They reported successful balloon isolation in 84% (185 of 220) of all treated PVs, which could be upgraded by the use of an additional linear cryocatheter to 99%. In our study, 92.5% (1,298 of 1,403 PVs) could be targeted with a cryoballoon alone, or the cryoballoons in combination with a cryotip catheter in 97% (1,360 of 1,403) of all targeted PVs. They also found a rare occurrence of atrial tachycardias after cryoballoon ablation (1 patient). Comparing the outcome of their short-term study with our results (median 12 months), in both studies the majority of patients remained free from AF after a single procedure. In the study by Jordaens *et al.* (11), all patients received antiarrhythmic drugs after the procedure. We found a success rate of 74% without the use of antiarrhythmic drug therapy and a further 5 patients without documented AF who received an additional empirical drug therapy from their treating physician. The main reason for this intermittent drug therapy was premature beats with short symptomatic palpitations. Several studies have demonstrated that complaints of palpitations often result from atrial or ventricular premature beats and are not an accurate predictor of recurrent AF (21).

In 58 patients, it was impossible to create a complete isolation of all PVs with the cryoballoon alone. In these circumstances, we achieve our therapeutic aim with the use of a large tip catheter to finish PVI. The main reason for the inability to achieve complete isolation was anatomic features such as oval-shaped PV ostia or inferior veins inserting onto the LA with a sharp angulation. In our experience, the potential learning curve in using this new technology is not a sufficient explanation in such situations with special anatomic features, and further device configuration would be helpful.

At the beginning of this study, it was unclear if a sole antral PVI strategy might be successful for the treatment of persistent AF, and so we also included 53 patients with persistent AF. The outcome in these patients was poor. We observed significant differences of atrial dimensions

between patients with PAF versus persistent AF in our study (Table 1). We speculate that one reason for poor outcome in persistent AF might be that the depth of penetration using the cryoballoon technique is inadequate. Possibly, the strategy of atrial PVI or the cryoballoon device does not produce sufficient substrate modification as required in persistent AF.

Complications. The major complication reported by Jordaens *et al.* (11) was PNP. In their study, all but one of the PNP cases occurred during a cryoablation with a 23-mm balloon. These results are supported by our findings. We found PNP in 24 of 26 patients who had ablation with a 23-mm balloon. Jordaens *et al.* (11) did not report on the findings of PNP in the long-term because only a short-term follow-up was presented. We observed the full recovery from PNP in our patients between some minutes after energy application up to 1 year after the ablation procedure.

Phrenic nerve injury is an important complication of AF ablation (4,22). Phrenic nerve injury has been seen more frequently with the use of balloon ablation catheters irrespective of the energy source (3,5) and with ablation in the right superior PV. The multicenter study of Sacher *et al.* (22) reported a complete recovery of phrenic nerve injury in 12 of 18 patients (66%) after 12 months. The latest recovery was observed after 19 months. However, in 3 patients, PNP had not recovered after 96 months. These patients remained symptomatic with dyspnea. The most common complication in our study was transient PNP. This complication resolved over time in all of our patients. To the best of our knowledge, no chronic phrenic nerve injury after transcatheter cryoballoon ablation has been reported in other studies. This seems to be different with high focus ultrasound ablation (4,5,10). Kuck *et al.* (10) reported that 2 of 15 patients (13.3%) treated with high-intensity focused ultrasound developed a right-sided PNP that did not resolve after 12 months follow-up. Natale *et al.* (4) reported only about a partial return of phrenic nerve function at the 3-month follow-up after circumferential ultrasound ablation for AF.

Pulmonary vein stenosis is a well-recognized complication of AF ablation using radiofrequency energy. Pulmonary vein stenosis can be prevented by avoiding radiofrequency energy application within a PV. However, the worldwide survey of AF ablation reported a 1.3% incidence of persistent PV stenosis. The preferred therapy for severe symptomatic PV stenosis is PV angioplasty, as recently recommended (8). In our study, no PV stenosis was observed despite ablation at the PV. This finding emphasizes that cryoenergy is safe with respect to PV stenosis in comparison with other energy forms.

Study limitations. The patients treated in this study suffered from paroxysmal or persistent AF. A conclusive comparison between the cryoballoon technology and radiofrequency ablation strategies requires randomized trials. We have no control group of patients in our study. In 41 patients (11.8%), antiarrhythmic drug therapy with amio-

darone or class I agents was not discontinued at the time of 3-month follow-up. Fifty-five patients (15.9%) were not accounted for in the final analysis of follow-up results as they did not complete follow-up beyond the blanking period.

Our results might be influenced by a learning curve as already discussed by others (11). No patients developed an atrio-esophageal fistula. Since the estimated incidence of atrio-esophageal fistula after radiofrequency ablation of AF has been reported to be less than 0.25% (1,23,24), the number of patients in our study is too small to definitely exclude this complication that follows cryoballoon ablation technology.

Conclusions

Sinus rhythm can be maintained in the majority of patients with PAF by means of circumferential PVI using cryoballoon ablation. However, this cryoballoon ablation strategy is not recommended in patients with persistent AF. Phrenic nerve injury is a potential, but not life-threatening, complication during the use of this balloon system. No PV stenosis or atrio-esophageal fistula occurred in our study.

Reprint requests and correspondence: Dr. Thomas Neumann, Department of Cardiology, Kerckhoff Heart Center, Benekestr. 2-8, 61231 Bad Nauheim, Germany. E-mail: t.neumann@kerckhoff-klinik.de.

REFERENCES

1. Cappato R, Calkins H, Chen SA, et al. A worldwide survey on the methods, efficacy, and safety of catheter ablation for human atrial fibrillation. *Circulation* 2005;111:1100-5.
2. Fuster V, Ryden LE, Crijns HJ, et al. ACC/AHA/ESC 2006 guidelines for the management of patients with atrial fibrillation—executive summary: a report of the American College of Cardiology/American Heart Association Task Force on Practice Guidelines and the European Society of Cardiology Committee for Practice Guidelines (Writing Committee to Revise the 2001 Guidelines for the Management of Patients With Atrial Fibrillation). *J Am Coll Cardiol* 2006;48:854-906.
3. Sarabanda AV, Bunch TJ, Johnson SB, et al. Efficacy and safety of circumferential pulmonary vein isolation using a novel cryothermal balloon ablation system. *J Am Coll Cardiol* 2005;46:1902-12.
4. Natale A, Pisano E, Shewchik J, et al. First human experience with pulmonary vein isolation using a through-the-balloon circumferential ultrasound ablation system for recurrent atrial fibrillation. *Circulation* 2000;102:1879-82.
5. Nakagawa H, Antz M, Wong T, et al. Initial experience using a forward directed, high-intensity focused ultrasound balloon catheter for pulmonary vein antrum isolation in patients with atrial fibrillation. *Pacing Clin Electrophysiol* 2007;18:136-44.
6. Avitall B, Lafontaine D, Rozmus G, et al. The safety and efficacy of multiple consecutive cryo lesions in canine pulmonary veins—left atrial junction. *Heart Rhythm* 2004;1:203-9.
7. Dill T, Neumann T, Ekinci O, et al. Pulmonary vein diameter reduction after radiofrequency catheter ablation for paroxysmal atrial fibrillation evaluated by contrast-enhanced three-dimensional magnetic resonance imaging. *Circulation* 2003;18:845-50.
8. Calkins H, Brugada J, Packer DL, et al. HRS/EHRA/ECAS expert consensus statement on catheter and surgical ablation of atrial fibrillation: recommendations for personnel, policy, procedures and follow-up. A report of the Heart Rhythm Society (HRS) Task Force on Catheter and Surgical Ablation of Atrial Fibrillation developed in partnership with the European Heart Rhythm Association (EHRA) and the European Cardiac Arrhythmia Society (ECAS); in collaboration with the American College of Cardiology (ACC), American Heart Association (AHA), and the Society of Thoracic Surgeons (STS). Endorsed and approved by the governing bodies of the American College of Cardiology, the American Heart Association, the European Cardiac Arrhythmia Society, the European Heart Rhythm Association, the Society of Thoracic Surgeons, and the Heart Rhythm Society. *Europace* 2007;9:335-79.
9. Natale A, Raviele A, Arentz T, et al. Venice Chart international consensus document on atrial fibrillation ablation. *J Cardiovasc Electrophysiol* 2007;18:560-80.
10. Schmidt B, Antz M, Ernst S, et al. Pulmonary vein isolation by high-intensity focused ultrasound: first-in-man study with a steerable balloon catheter. *Heart Rhythm* 2007;4:575-84.
11. Van Belle Y, Janse P, Rivero-Ayerza MJ, et al. Pulmonary vein isolation using an occluding cryoballoon for circumferential ablation: feasibility, complications, and short-term outcome. *Eur Heart J* 2007;28:2231-7.
12. Lemery R, Veinot JP, Tang AS, et al. Fiberoptic balloon catheter ablation of pulmonary vein ostia in pigs using photonic energy delivery with diode laser. *Pacing Clin Electrophysiol* 2002;25:32-6.
13. Reddy VY, Houghtaling C, Fallon J, et al. Use diode laser balloon ablation catheter to generate circumferential pulmonary venous lesions in an open-thoracotomy caprine model. *Pacing Clin Electrophysiol* 2004;27:52-7.
14. Pappone C, Manguso F, Vicedomini G, et al. Prevention of iatrogenic atrial tachycardia after ablation of atrial fibrillation: a prospective randomized study comparing circumferential pulmonary vein ablation with a modified approach. *Circulation* 2004;110:3036-42.
15. Karch MR, Zrenner B, Deisenhofer I, et al. Freedom from atrial tachyarrhythmias after catheter ablation of atrial fibrillation: a randomized comparison between 2 current ablation strategies. *Circulation* 2005;111:2875-80.
16. Kottkamp H, Tanner H, Kobza R, et al. Time course and quantitative analysis of atrial fibrillation episode number and duration after circular plus linear left atrial lesions: trigger elimination or substrate modification: early or delayed cure? *J Am Coll Cardiol* 2004;44:869-77.
17. Cheema A, Dong J, Dalal D, et al. Long-term safety and efficacy of circumferential ablation with pulmonary vein isolation. *J Cardiovasc Electrophysiol* 2006;10:1080-5.
18. Pappone C, Rosanio S, Augello G, et al. Mortality, morbidity, and quality of life after circumferential pulmonary vein ablation for atrial fibrillation: outcomes from a controlled nonrandomized long term study. *J Am Coll Cardiol* 2003;42:185-97.
19. Jais P, Hocini M, Hsu LF, et al. Technique and results of linear ablation at the mitral isthmus. *Circulation* 2004;110:2996-3002.
20. Oral H, Chugh A, Good E, et al. A tailored approach to catheter ablation of paroxysmal atrial fibrillation. *Circulation* 2006;113:1824-31.
21. Klemm HU, Ventura R, Rostock T, et al. Correlation of symptoms to ECG diagnosis following atrial fibrillation ablation. *J Cardiovasc Electrophysiol* 2006;17:146-50.
22. Sacher F, Monahan KH, Thomas SR, et al. Phrenic nerve injury after atrial fibrillation catheter ablation. Characterization and outcome in a multicenter study. *J Am Coll Cardiol* 2006;47:2498-503.
23. Scanavacca MI, Davila A, Parga J, Sosa E. Left atrial-esophageal fistula following radiofrequency catheter ablation of atrial fibrillation. *J Cardiovasc Electrophysiol* 2004;15:960-2.
24. Pappone C, Oral H, Santinelli V, et al. Atrio-esophageal fistula as a complication of percutaneous transcatheter ablation of atrial fibrillation. *Circulation* 2004;109:2724-6.

Key Words: ablation ■ arrhythmia ■ cryoballoon ■ catheter ablation ■ tachyarrhythmias ■ atrial fibrillation ■ pulmonary veins.

**Circumferential Pulmonary Vein Isolation With the Cryoballoon Technique:
Results From a Prospective 3-Center Study**

Thomas Neumann, Jürgen Vogt, Burghard Schumacher, Anja Dorszewski, Malte Kuniss, Hans Neuser, Klaus Kurzidim, Alexander Berkowitsch, Marcus Koller, Johannes Heintze, Ursula Scholz, Ulrike Wetzel, Michael A.E. Schneider, Dieter Horstkotte, Christian W. Hamm, and Heinz-Friedrich Pitschner

J. Am. Coll. Cardiol. 2008;52:273-278

doi:10.1016/j.jacc.2008.04.021

This information is current as of July 16, 2008

Updated Information & Services	including high-resolution figures, can be found at: http://content.onlinejacc.org/cgi/content/full/52/4/273
References	This article cites 24 articles, 14 of which you can access for free at: http://content.onlinejacc.org/cgi/content/full/52/4/273#BIBL
Rights & Permissions	Information about reproducing this article in parts (figures, tables) or in its entirety can be found online at: http://content.onlinejacc.org/misc/permissions.dtl
Reprints	Information about ordering reprints can be found online: http://content.onlinejacc.org/misc/reprints.dtl

