



Early recovery of pulmonary vein conduction after cryoballoon ablation for paroxysmal atrial fibrillation: a prospective study

Gian Battista Chierchia^{1*}, Carlo de Asmundis¹, Stephan-Andreas Müller-Burri¹, Andrea Sarkozy¹, Lucio Capulzini¹, Gaetano Paparella¹, Sergio Chierchia², Markus Roos¹, and Pedro Brugada¹

¹Heart Rhythm Management Center, UZ Brussel-VUB, Laarbeeklaan 101, 1090 Brussels, Belgium; and ²Villa Azzurra Hospital, GVM, Rapallo (GE), Italy

Received 8 October 2008; accepted after revision 24 November 2008

Aims

To assess the incidence of early pulmonary vein (PV) reconnection, characterize the anatomic features of the re-conducting veins, and analyse the time course of their recovery in a series of consecutive patients with paroxysmal atrial fibrillation (AF) undergoing ablation with the Arctic Front Cryoballoon.

Methods and results

We prospectively enrolled 26 patients (20 males; age 55.4 ± 4.1) for circumferential PV cryoballoon isolation for highly symptomatic paroxysmal AF. Following isolation of all veins, we analysed PV potentials in each vein after 30 and 60 min with a circular mapping catheter. After successful electrical isolation of all 104 PV's, recurrence was observed only in three veins (2.8%) after 30 min. Two further cryoballoon applications in each of these veins lead to their isolation. These veins were still electrically disconnected at 60 min. No PV reconnection was observed in any of the other 101 veins (97.1%) at 30 and 60 min.

Conclusion

Cryoballoon ablation of the PV's ostia is a very effective technique to achieve electrical isolation, with a very low rate of early reconnection.

Introduction

Since the demonstration that pulmonary vein (PV) ectopic activity is a main trigger of paroxysmal atrial fibrillation (AF),^{1,2} radiofrequency ablation (RF) of this arrhythmia has become an increasingly popular procedure in many electrophysiology laboratories. Nowadays creation of circumferential lesions around the PVs is certainly the most widespread technique to achieve PV isolation (PVI). Furthermore, growing evidence emphasizes the importance of achieving complete PVI for a successful long-term outcome.^{3,4} However, recent data report that early recovery of PV conduction after RF catheter ablation occurs in a substantial number of veins.^{5,6} These studies suggest an association between this event and the recurrence of the arrhythmia, and propose that further isolation of early recovered PV conduction is likely to improve the long-term success.^{3,7} Traditionally, RF-based PVI uses a 'point-by-point' ablation technique, which makes it difficult to create continuous ablation lines and allows conduction gaps to develop which may facilitate recurrence of the arrhythmia.

Although a novel catheter-based approach using the cryoballoon (Arctic Front, Cryocath, Montréal, Quebec, Canada) has proven very effective in accomplishing PVI,^{8,9} no study has assessed the possibility that early recovery of PV conduction may occur shortly after cryoballoon ablation.

In a series of consecutive patients with paroxysmal AF undergoing ablation with the Arctic Front Cryoballoon, we assessed the incidence of early PV reconnection, characterized the anatomic features of the re-conducting veins, analysed the time course of their recovery, and attempted to investigate the technical pitfalls that might have contributed to the early failure.

Material and methods

Patient characteristics

We prospectively enrolled 26 patients (20 males; age 55.4 ± 4.1) for circumferential PV cryoballoon isolation for highly symptomatic

* Corresponding author. Tel: +32 2 4763038, Fax: +32 2 4776840, Email: jeanbaptiste.chierchia@uzbrussel.be

Published on behalf of the European Society of Cardiology. All rights reserved. © The Author 2008. For permissions please email: journals.permissions@oxfordjournals.org.

paroxysmal AF. All patients provided informed consent prior to the procedure. Inclusion criteria were based on the frequent occurrence of recurrent episodes of AF, self-terminating within 7 days, and developing in spite of treatment with at least two anti-arrhythmic drugs. On average, patients presented with the arrhythmia 3.2 ± 0.7 years prior to enrolment. Structural heart disease (coronary artery disease) was present in two patients (7.7%) (Table 1).

To exclude the presence of thrombi in the left atrial appendage, all patients underwent two-dimensional *trans*-oesophageal echocardiography (TEE) the day before the procedure, along with a *trans*-thoracic examination (TTE) enabling assessment of LA dimensions, LV, and valvular function. Exclusion criteria were the presence of a left atrial thrombus, a history of cerebro-vascular attacks, severe uncontrolled heart failure, contraindications to general anaesthesia or LA dimensions >50 mm.

Ablation procedure

Before the procedure, detailed information on left atrial anatomy was obtained by two-dimensional TTE, TEE, as well as by computed tomography. Ablation was performed under general anaesthesia.

A 6 Fr pigtail catheter was positioned in the aortic root via a left femoral approach to monitor arterial pressure and to assess the position of the aorta. A 6 Fr quadripolar catheter was inserted in the right jugular vein and advanced to the coronary sinus. A single trans-septal puncture was then performed under fluoroscopic guidance, using the right femoral venous approach. After gaining left atrial access, a 70 U/kg heparin iv bolus was given. A 0.32 F Emerald exchange wire (Cordis, Johnson and Johnson, Diamond Bar, CA, USA) was advanced in the left superior PV and a steerable 15 F over-the-wire sheath (FlexCath, Cryocath) was positioned in the left atrium. A circular mapping catheter (Lasso, Biosense Webster, Inc., Diamond Bar, CA, USA) was then advanced in each PV ostium to obtain baseline electrical information. After withdrawing the mapping catheter, a 28 mm double walled cryoballoon (Arctic Front, Cryocath) was advanced over the wire up to the left atrium, inflated and positioned in the PV ostium of each vein (Figure 1). Optimal vessel occlusion was considered to have been achieved when selective contrast injection showed total contrast retention with no backflow in the atrium. For each vein, cryoablation consisted of a minimum of two applications lasting 5 min each. Whenever possible, we tried to engage two different branches of the same vein and to orient

Table 1 Patients characteristics

Patient number	Sex	Age	AF onset (year)	Type of AF	Risk factors	Heart disease	Anti-arrhythmic drugs	Previous ablation	LA Dim. (mm)	Ejection fraction (%)
1	M	54	2.5	Paroxysmal	NO	NO	IC	NO	50	55
2	M	55	3	Paroxysmal	Hypertension	NO	BB	NO	44	55
3	M	60	3	Paroxysmal	NO	NO	IC	NO	40	50
4	M	54	3.5	Paroxysmal	NO	NO	IC	NO	50	55
5	F	56	3	Paroxysmal	NO	NO	IC	NO	44	55
6	M	60	3.5	Paroxysmal	NO	NO	IC	NO	40	50
7	M	57	3	Paroxysmal	NO	NO	IC	NO	50	55
8	F	58	3.5	Paroxysmal	Hypertension	NO	BB	NO	44	55
9	M	60	5	Paroxysmal	NO	NO	IC	NO	40	50
10	M	54	3	Paroxysmal	Hypertension	NO	BB	NO	50	55
11	M	55	2.5	Paroxysmal	NO	NO	IC	NO	44	55
12	M	60	3	Paroxysmal	Hypertension	Cad	BB	NO	40	50
13	M	52	2.5	Paroxysmal	NO	NO	IC	NO	50	55
14	F	55	2.5	Paroxysmal	Hypertension	NO	BB	NO	44	55
15	M	60	3.5	Paroxysmal	NO	NO	IC	NO	40	50
16	M	57	3	Paroxysmal	NO	NO	IC	NO	50	55
17	M	54	3	Paroxysmal	NO	NO	IC	NO	50	55
18	M	46	5	Paroxysmal	NO	NO	IC	NO	45	50
19	F	58	4	Paroxysmal	NO	NO	IC	AVNRT	44	55
20	M	47	3	Paroxysmal	NO	NO	IC	NO	42	60
21	M	61	3.5	Paroxysmal	Hypertension	NO	BB	NO	38	60
22	F	56	2.5	Paroxysmal	NO	NO	IC	NO	42	55
23	M	45	2.5	Paroxysmal	NO.	NO	IC	NO	45	55
24	M	55	3	Paroxysmal	Hypertension	Cad	BB	NO	45	50
25	F	57	3.5	Paroxysmal	Hypertension	NO	BB	RA Flu	46	55
26	M	56	3.5	Paroxysmal	NO	NO	IC	NO	42	60

AF, atrial fibrillation; AVNRT, AV nodal re-entry tachycardia; BB, β -blockers; CAD, coronary artery disease; IC, class IC anti-arrhythmic drugs; LA Dim, left atrium dimension; RA Flu, right atrium flutter.

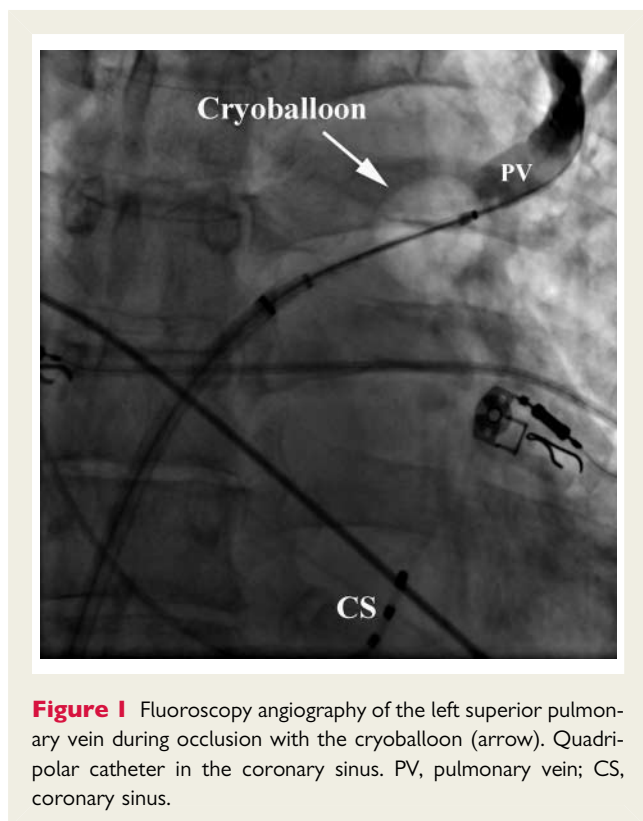


Figure 1 Fluoroscopy angiography of the left superior pulmonary vein during occlusion with the cryoballoon (arrow). Quadripolar catheter in the coronary sinus. PV, pulmonary vein; CS, coronary sinus.

the balloon differently, in the attempt of covering a wider ostial surface. However, if successful occlusion could only be obtained in one branch, both applications were delivered by leaving the guide-wire in the same branch. Usually, the left superior pulmonary vein (LSPV) was treated first, followed by the left inferior (LIPV), right superior (RSPV), and right inferior (RIPV). In order to avoid phrenic nerve palsy, a complication observed during right superior PV ablation with the cryoballoon, a quadripolar catheter was inserted in the superior vena cava, and diaphragmatic stimulation was achieved by pacing the ipsilateral phrenic nerve with a 1000 ms cycle and a 12 mA output. The reason of pacing at such a slow rate was to prevent catheter displacement, due to diaphragmatic contraction, in the early phases of application. During the whole procedure, activated clotting time was maintained over 300 s by supplementing heparin infusion, as required.

Assessment of pulmonary vein isolation

As described for RF circumferential PVI,^{5,6} we recorded PV activity before, immediately after ablation, and 30 and 60 min thereafter. In order to memorize the location of recorded potentials, positions of the circular mapping catheter were recorded fluoroscopically in left lateral and anterior–posterior views in each PV ostium before ablation. Effective PVI was considered to have been obtained when all PV potentials were abolished or dissociated from atrial activity, and bidirectional block (entry plus exit block) was documented. Entry block was demonstrated by the absence of PV activity while pacing in the distal CS. Exit block was verified by pacing from each bipolar pair of the mapping catheter in the PV at 10 mA and 2 ms pulse width (Figure 2).

Statistical analysis

Continuous variables are expressed as mean \pm SD. Categorical variables are expressed as percentages.

Results

Total procedure time including the 60 min post-ablation observation period was 175 ± 43 min. Total fluoroscopy time was 42 ± 11 min. Total number of veins was 104. Three left-sided common ostia were found. Mean left atrial size was 44.6 ± 3.8 mm. Throughout all procedures, patients remained in sinus rhythm and no one developed AF at any stage of the procedure. Thanks to the excellent steerability of both the FlexCath (Cryocath) and the Lasso (Biosense Webster), it was possible to map all PV ostia. Potentials were present in all PV ostia before ablation. Successful occlusion could be obtained in 97 PVs (93.2%). In five PVs, we performed more than two cryoablations as optimal occlusion could not be reached with the first two, and three applications were performed in five individual patients, respectively in two RIPV, one LSPV, and two LIPV. Immediately after initial ablation, PVI could be demonstrated in 97 PVs (93.2%). Bidirectional block was present in all these veins at first testing after ablation. Of the seven veins (6.7%) in which isolation could not be achieved, four were RIPV (3.8%) and three LIPV (2.8%). In all seven veins, bidirectional conduction could be demonstrated. These were successfully treated by two further applications so that complete isolation of all 104 PVs could be obtained at the end of the procedure (100%). No complications occurred at any stage of ablation. Transient phrenic nerve palsy was observed in one patient while delivering energy in the RSPV. Diaphragmatic stimulation completely recovered 10 min after cessation of energy application.

Post-ablation period

Thirty minutes following the last application, reconnection had occurred only in three (2.8%) of the 104 isolated PVs. These veins were all RIPV, and reconnection was present in the inferior portion in two and in the posterior portion in one. Residual PV potentials were recorded on three bipolar pairs of the circular mapping catheter in the vein in which reconnection occurred in its posterior portion and on two bipolar pairs in the inferior portion of the two reconnected other veins. Two further cryoballoon applications targeting the lower part of the vessel resulted in effective electrical isolation. Thirty minutes following these applications, these veins were still electrically isolated. No PV reconnection was observed in any of the other 101 veins (97.1%) at 30 and 60 min. Thus, at the end of our observational period of 60 min, electrical isolation was present in all 104 veins (100%).

Short-term follow-up

In the 4 weeks following the procedure, no patient referred any recurrence of arrhythmic episodes. On the 24 h ECG Holter monitoring performed 4 weeks after ablation, no episode of AF nor atrial arrhythmia was documented in any patient.

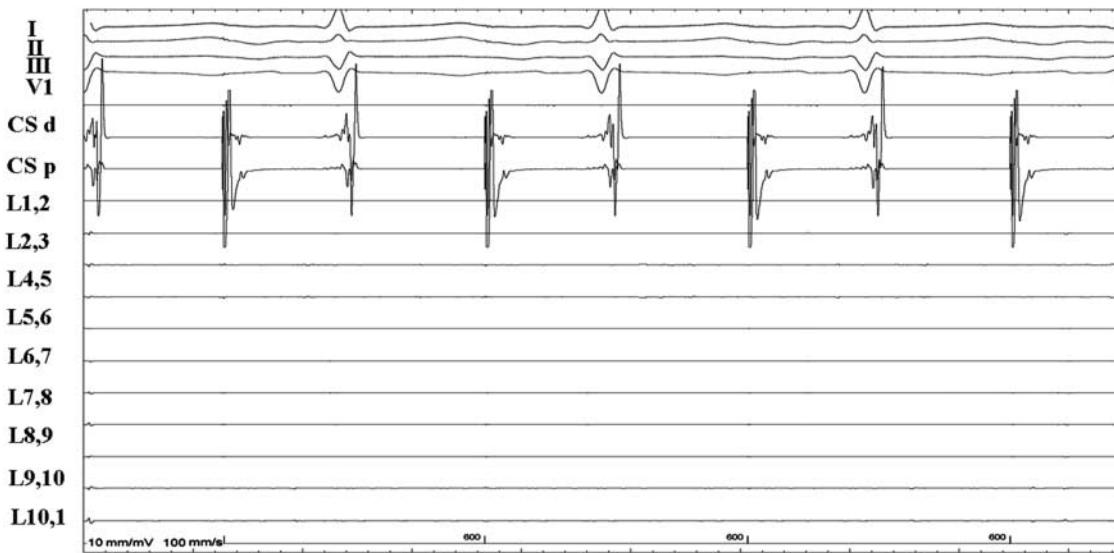


Figure 2 Intra-cardiac electrogram showing pacing from the proximal coronary sinus (CS p) with the absence of pulmonary vein potentials recorded on the circular multi-electrode mapping catheter (L1,2 to L10,1) placed in a pulmonary vein ostium after cryoballoon ablation.

Discussion

Substantial evidence indicates that complete PVI might be essential to maintain long-term success following ablation of AF. In fact, recovery of PV conduction could be associated with a poor outcome and account for most recurrences, despite initial success.^{10,11} Thus, recognition and treatment of early PV reconnection might prove crucial for assessing the long-term effects of AF ablation.

Early recovery of PV conduction after RF catheter ablation occurs in a substantial number of veins. Cheema *et al.*⁵ analysed the incidence and time course of this phenomenon in a population of 14 patients undergoing RF catheter ablation guided by an electro-anatomical mapping system. Sixty minutes after complete electrical isolation, recurrence of PV conduction had occurred in 50% of veins and in 93% of patients. Pulmonary vein reconnection was observed in one-third of the veins after 30 min and in another one-fifth after 1 h. Wang *et al.*⁶ evaluated the impact of early PV reconnection on the procedural success rate on a mean 7 months follow-up in a cohort of patients undergoing RF ablation for paroxysmal AF. These authors concluded that acute reconnection occurred in ~30% of PV and that re-isolation of recovered conduction improved the overall success rate. Similarly, Sauer *et al.*¹² described 24% of early PV reconnection in a large cohort of patients undergoing AF ablation.

Cryoballoon technology is a novel technology used to achieve circumferential PVI in patients affected by drug-resistant paroxysmal AF. Acutely, this technique affords successful isolation in ~90–100% of veins,^{11,13} but data on incidence, anatomical, and procedural features, as well as on the time course of early recovery of PV conduction are not available. Two recent studies assessing the immediate efficacy of this technique,^{8,9} analysed a short (30 min) post-ablation observation period to assess persistence of PVI. Although conducted on a small population, our findings

are interesting. Not only we confirm the efficacy of this technique in obtaining PVI, but we also show that early PV reconnection might be extremely rare after ablation with a 28 mm cryoballoon. In fact, PV reconnection occurred in only 3 of 104 (2.8%) veins during a 60 min post-ablation period. These veins were all RIPV and electrical reconnection could be observed in the inferior portion in two and in the posterior portion in one. In our experience, isolating the RIPV proved more difficult than treating other veins. This is not surprising since, in view of its posterior orientation, balloon handling in the RIPV ostium is often difficult.

Early recovery of PV conduction might occur more frequently after RF circumferential PVI than following cryoballoon application. Various factors could explain this observation. First, circumferential PVI using a RF catheter is done using a 'point-by-point' approach. Therefore, this technique remains complex, time-consuming, and heavily dependent on operator's skills. Furthermore, in order to avoid stenosis, PVI is targeted to the antrum. However, ablating in the PV antra requires the creation of larger lines in a thicker tissue. As a result, conduction gaps are more likely to occur and achieving transmural becomes more difficult, due to tissue thickness. Moreover, to avoid oesophageal injury, RF power is often lowered when ablating on the posterior wall. This results in further difficulty in creating deeper lesions in this region. Finally, anatomical structures such as the ridge separating left atrial appendage from the LSPV offer limited stability and poor catheter tip-tissue contact.¹⁴

Cryoballoon technology might overcome some of these drawbacks. First, this technique offers the advantage of creating more continuous lesions due to a superior catheter-tissue interaction. In fact, compared with those obtained with RF, cryolesions appear more homogeneous and show little or no persistence of viable myocytes,^{15–17} with less probability for gaps to occur in the circumferential lines. Moreover, by its own nature, cryoenergy

'sticks' to the endocardium, when reaching low temperature, thus ensuring better catheter stability in the ostium and optimal catheter-wall contact. Furthermore, energy is deployed on the whole balloon surface. These features might help achieving transmural lesions in anatomically unfavourable regions. Finally, cryoenergy might be safer than RF. Substantial evidence indicates that the risk of PV stenosis is minimal and no atrio-oesophageal fistula has been yet reported with cryoballoon ablation.

In our experience, early recurrence of PV conduction occurred only in 3 of 104 veins and was readily reversed by further applications. However, follow-up studies in patients submitted to cryoballoon AF ablation report an AF recurrence rate ranging between 40 and 14%, despite successful isolation of nearly all veins during the procedure.^{8,18} The apparent discrepancy between our findings and the relatively high incidence of AF recurrence observed during late follow-up is difficult to explain. First, it is conceivable that factors other than early recovery of PV conduction might play a role in determining AF recurrence. One possible explanation to this phenomenon could be that PV reconnection after cryoballoon ablation might occur later. In fact our study only analyses early PV reconnection in a post-ablation observational time of 60 min. Future studies analysing the evolution in time of the cryoballoon lesion are needed to answer this question. Additionally, this technique might leave the PV antrum largely unablated.¹³ Substantial evidence suggests that electrical isolation of PV antra during AF ablation could improve the long-term success.¹⁹ Finally, although the studies mentioned above would suggest that early recovery of PV conduction following AF ablation could be associated with poor outcome and account for most AF recurrence,^{5,6,12} the data available today are still too limited to make such an assumption.

Limitations of the study

Our study bares the obvious limitation of a small patient population. Prospective studies with larger populations will be needed to confirm our findings. Furthermore, there is no existing consensus on how long we should monitor early recurrence after ablation. Waiting longer than 60 min might have resulted in a higher incidence of reconnected PV's. Furthermore, a longer follow-up to evaluate the clinical course of these patients is needed.

Conclusion

Cryoballoon ablation of the PV's ostia is a very effective technique to achieve electrical isolation, with a very low rate of early reconnection. However, studies conducted on larger populations are warranted in order to confirm our findings.

Conflict of interest: none declared.

References

- Chen YJ, Chen SA. Electrophysiology of the pulmonary veins. *J Cardiovasc Electrophysiol* 2006;**17**:220–4.
- Haissaguerre M, Jais P, Shah D, Takahashi A, Hocini M, Quiniou G et al. Spontaneous initiation of atrial fibrillation by ectopic beats originating in the pulmonary veins. *N Engl J Med* 1998;**339**:659–66.
- Cheema A, Dong J, Dalal D, Vasarmmeddy CR, Marine JE, Enrikson CA et al. Long term safety and efficacy of circumferential ablation with pulmonary vein isolation. *J Cardiovasc Electrophysiol* 2006;**17**:1080–5.
- Lemola K, Oral H, Chugh A, Hall B, Cheung P, Han J et al. Pulmonary vein isolation as end point for left atrial circumferential ablation of atrial fibrillation. *J Am Coll Cardiol* 2005;**46**:1060–6.
- Cheema A, Dong J, Dalal D, Marine JE, Enrikson CA, Spragg D et al. Incidence and time course of early recovery of pulmonary vein conduction after catheter ablation of atrial fibrillation. *J Cardiovasc Electrophysiol* 2007;**18**:387–91.
- Wang X, Liu X, Sun Y, Gu J, Shi H, Zhou L et al. Early identification and treatment of PV re-connections: role of observation time and impact on clinical results of atrial fibrillation ablation. *Europace* 2007;**9**:481–6.
- Verma A, Kilicaslan F, Pisano E, Marrouche NF, Fanelli R, Brachmann J et al. Response of atrial fibrillation to pulmonary vein antrum isolation is directly related to resumption and delay of pulmonary vein conduction. *Circulation* 2005;**112**:627–35.
- Klein G, Oswald H, Gardiwal A, Lusebrink U, Lissel C, Yu H et al. Efficacy of pulmonary vein isolation by cryoballoon ablation in patients with paroxysmal atrial fibrillation. *Heart Rhythm* 2008;**5**:802–6.
- Neumann T, Vogt J, Schumacher B, Dorszewski A, Kuniss M, Neuser H et al. Circumferential pulmonary vein isolation with the cryoballoon technique results from a prospective 3-center study. *J Am Coll Cardiol* 2008;**52**:273–8.
- Gerstenfeld EP, Callans DJ, Dixit S, Zado E, Marchlinski FE. Incidence and location of focal atrial fibrillation triggers in patients undergoing repeat pulmonary vein isolation: implications for ablation strategies. *J Cardiovasc Electrophysiol* 2003;**14**:685–90.
- Nanthakumar K, Plumb VJ, Epstein AE, Veenhuizen GD, Link D, Kay GN. Resumption of electrical conduction in previously isolated pulmonary veins: rationale for a different strategy? *Circulation* 2004;**109**:1226–9.
- Sauer WH, Mc Kernan ML, Lin D, Gerstenfeld EP, Callans DJ, Marchlinski FE. Clinical predictors and outcomes associated with acute return of pulmonary vein conduction during pulmonary vein isolation for treatment of atrial fibrillation. *Heart Rhythm* 2006;**3**:1024–8.
- Reddy V, Neuzil P, D'Avila A, Laragy M, Malchiano Z, Kralovec S et al. Balloon catheter ablation to treat paroxysmal atrial fibrillation: what is the level of pulmonary venous isolation? *Heart Rhythm* 2008;**5**:353–60.
- Mansour M, Refaat M, Heist EK, Mela T, Cury R, Holmvang G et al. Three-dimensional anatomy of the left by magnetic resonance angiography: implications for catheter ablation for atrial fibrillation. *J Cardiovasc Electrophysiol* 2006;**17**:719–23.
- Thibault B, Villemaire C, Talajic M. Catheter cryoablation is a more effective and potentially safer method to create atrial conduction block: comparison with radiofrequency ablation. *Semin Interv Cardiol* 1997;**2**:251–65.
- Rodriguez LM, Leunissen J, Hoekstra A, Korteling BJ, Smeets JL, Timmermans C et al. Transvenous cold mapping and cryoablation of the AV node in dogs: observations of chronic lesions and comparison to those obtained using radiofrequency ablation. *J Cardiovasc Electrophysiol* 1998;**9**:1055–61.
- Shyu KG, Cheng JJ, Chen JJ, Lin JL, Lin FY, Tseng YZ et al. Recovery of atrial function after atrial compartment operation for chronic atrial fibrillation in mitral valve disease. *J Am Coll Cardiol* 1994;**24**:392–8.
- Van Belle Y, Janse P, Rivero-Ayerza M, Thornton A, Jessurun E, Theuns D et al. Pulmonary vein isolation using an occluding cryoballoon for circumferential ablation: feasibility, complications, and short-term outcome. *Eur Heart J* 2007;**28**:2231–7.
- Verma A, Marrouche NF, Natale A. Pulmonary vein antrum isolation: intracardiac echocardiography-guided technique. *J Cardiovasc Electrophysiol* 2004;**15**:1335–40.