

Safety and Efficacy of Cryoablation in Perinodal Accessory Pathways

Hamid Bastani, Frieder Braunschweig, Nikola Drca, Per Insulander, Göran Kennebäck, Bitu Sadigh, Jonas Schwieler, Fariborz Tabrizi, Mats Jensen-Urstad
 Dept of Cardiology, Karolinska Institute, Karolinska University Hospital, Stockholm Sweden

CONCLUSION

Cryoablation of anteroseptal and midseptal accessory pathways is a safe and effective alternative to radiofrequency therapy.

BACKGROUND

Radiofrequency ablation in the septum close to the atrioventricular (AV) node or His bundle has an increased risk of irreversible complications.

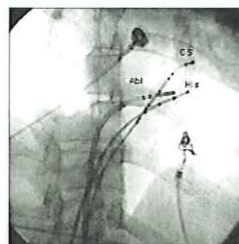
Cryothermal energy has the advantages of reversible cryomapping and increased catheter stability.

We have evaluated the safety and efficacy of cryoablation in midseptal and anteroseptal accessory pathways.

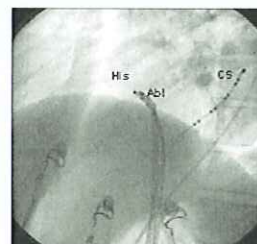
METHOD

Between 2004 and 2007 18 consecutive patients underwent cryoablative procedures for accessory pathways (AP) either located at the anteroseptal (n=13) or midseptal (n=5) area.

Three patients had dual APs. Cryomapping, using a 6mm tip catheter, at -30°C was performed before ablation with a goal temperature of -75°C for 240 seconds.

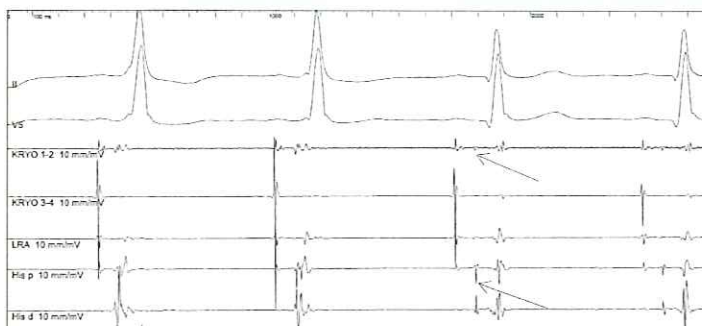


RAO



LAO

Fluoroscopy shows the site of a successful cryoablation (Ab1) in close proximity to the His catheter (His). RAO: right anterior oblique; LAO: left anterior oblique



Anteroseptal AP. ECG during cryomapping shows the elimination of preexcitation. There is a clear His potential (arrow) seen in the cryoablation catheter.

PATIENTS

	Number
Men	11 (61%)
Women	7 (39%)
Age, median (range)	27(17-62)
Overt WPW	15 (83%)
Concealed WPW	3 (17%)
No underlying heart disease	15 (83%)

RESULTS

Substrate	Number	Success	Recurrence	Success after redo
Anteroseptal	13	12	3	11/13
Midseptal	5	5	2	5/5
Total	8	17	5	16/18

Total procedure time was 163±54 minutes and the fluoroscopy time was 29±18 minutes. Follow-up was 682±373 days. Transient prolongation of AH interval was observed in one patient with anteroseptal AP during cryoablation. There was no permanent damage to the conduction system.